

Restoring Facial Contour and Harmony Using Biphasic Calcium Phosphate Bioceramics

Oromar Moreira Filho, MD*
 Francisco H.L. Wykrota, MD†
 Sonja Ellen Lobo, DDS, MSc,
 PhD†

Background: The restoration of facial contour is one of the pillars for the treatment of facial disharmonies and deformities. Fat transplantation and fillers have been widely used to improve the positioning of soft tissues, which are, however, directly related to the conditions and positioning of the underlying bone tissue. Recontouring of the latter has been performed using osteotomies and several types of bone grafts or biomaterials, as inlay or onlay grafts/implants. Here, biphasic calcium phosphate bioceramics were applied in a series of cases, their long-term results are shown, and their advantages, discussed.

Methods: A retrospective analysis of 20 patients, who were subjected to facial recontour with onlay implants of biphasic calcium phosphate bioceramics, is reported. Patients were seeking to improve facial harmony due to congenital deformities, trauma, tumor resection or signs of aging, and were followed for up to 16 years. Clinical data, radiographic images, and information regarding pain and other findings were retrieved from medical records.

Results: Six patients were men and 14 were women. Their ages ranged from 19 to 64 years. Bioceramics were implanted under the periosteum through external or intraoral incisions. Some patients underwent combined procedures, such as rhinoplasties or facial lifting. None of the patients presented exacerbated inflammation or pain. One of them had infection in the intraoral incision, which was resolved with medication.

Conclusion: All patients had improved facial contours following the use of bioceramics to augment bone tissue and presented stable results at long-term evaluation. (*Plast Reconstr Surg Glob Open* 2021;9:e3516; doi: [10.1097/GOX.0000000000003516](https://doi.org/10.1097/GOX.0000000000003516); Published online 8 April 2021.)

INTRODUCTION

Congenital malformations, trauma, infection, tumors, and aging are common causes of facial disharmonies or deformities. Treatment involves restoration of facial contour using osteotomies, bone grafts, implant of biomaterials,¹⁻⁵ fat transplantation,^{6,7} or injections of soft tissue fillers and neuromodulators, to reverse signs of facial aging.^{8,9}

Bone, cartilage grafts, and a wide variety of biomaterials, with distinct physicochemical properties and presentation forms, have been used. Biomaterials (alloplastic) have several advantages over autografts and allografts, including biosafety, unlimited off-shelf availability, reduced surgical

time, ease of handling, reduced trauma due to absence of surgical procedures for harvesting, and the possibility of being fabricated specifically for each patient and for a given surgical site.¹⁰⁻¹²

Polymeric biomaterials such as silicone, porous high-density polyethylene (eg, Medpor), polytetrafluorethylene, polyethylene terephthalate (Mersilene mesh), expanded polytetrafluorethylene, and polymethylmethacrylate have been used for a long time because they are cheap and may be readily shaped and applied.^{10,13,14} However, clinical results have been inconsistent, with reports of several adverse effects, such as infection, edema, erythema, irregular contour, and undesirable fibrous tissue formation around and/or inside the implant.^{2,10,14,15} Biomaterials that stimulate such biological responses, consistent with foreign body reactions, should no longer be called biocompatible, but biotolerant.^{12,16,17}

In this context, biphasic calcium phosphate (BCP) bioceramics, composed by an intimate mixture of hydroxyapatite (HA) and β -tricalcium phosphate (β -TCP), are of special interest. Some (particularly those with

From the *Department of Plastic Surgery, Hospital Santa Casa de Misericórdia de Belo Horizonte, Minas Gerais, Brazil; and †EINCO Biomaterial Ltda., Belo Horizonte, Minas Gerais, Brazil. Received for publication August 9, 2020; accepted January 7, 2021.

Copyright © 2021 The Authors. Published by Wolters Kluwer Health, Inc. on behalf of The American Society of Plastic Surgeons. This is an open-access article distributed under the terms of the [Creative Commons Attribution-Non Commercial-No Derivatives License 4.0 \(CCBY-NC-ND\)](https://creativecommons.org/licenses/by-nc-nd/4.0/), where it is permissible to download and share the work provided it is properly cited. The work cannot be changed in any way or used commercially without permission from the journal.

DOI: [10.1097/GOX.0000000000003516](https://doi.org/10.1097/GOX.0000000000003516)

Disclosure: Dr Wykrota serves as the CEO at EINCO Biomaterial Ltda., and Dr Lobo is EINCO's researcher. Dr Moreira Filho has no financial interest in relation to the content of this article. No funding was received for this article.

interconnected micro-, meso-, and macropores and nanostructured surface) are biocompatible, bioactive, osteoconductive, biomimetic, and can be fabricated in distinct presentation forms (ie, granules of different sizes, cages, blocks, wedges, and individualized custom-made pieces, based on CT scans). Furthermore, they are stable over time (depending upon the HA/ β -TCP ratio, they are not resorbed/solubilized before a new bone is formed) and present intrinsic osteoinduction properties.^{5,11,15,18–22} These bioceramics have been considered the gold standard, among alloplastic biomaterials for bone reconstructions.²³

A BCP bioceramic (Osteosynt, EINCO Biomaterial Ltda, Belo Horizonte, Brazil) has been successfully applied in orthopedics²⁴ and in craniofacial reconstructions.²⁵ However, its long-term clinical evaluation, as onlay implant to restore facial recontour, has not been reported yet.

METHODS

This retrospective study was approved by the Research Ethics Committee of Hospital Santa Casa de Misericórdia, Belo Horizonte (Minas Gerais, Brazil) and by the Brazilian National Committee on Research Ethics (SISNEP—Sistema Nacional de Informação sobre Ética em Pesquisa envolvendo Seres Humanos—approval number CAAE 82752718.5.0000.5138). Written informed consent was obtained from each patient.

A retrospective analysis of facial contour and harmony of patients treated with the BCP bioceramic Osteosynt (EINCO Biomaterial Ltda, Belo Horizonte, Minas Gerais, Brazil), composed by an intimate mixture of HA and β -TCP, and presenting interconnected micro-, meso-, and macropores and nanostructured surface topography, in the form of granules and a custom-made piece, was conducted. All surgeries were performed by the same plastic surgeon (OM).

Twenty patients were included and grouped according to the facial thirds where the biomaterial was implanted, ie, upper third, middle third (Figs. 1, 2), and lower third of the face (Figs. 3, 4). Only patients who received the bioceramics as onlay implants and who had at least 3 years of postoperative follow-up were included. There were 14 female and 6 male patients; their ages ranged from 19 to 64 years (average 37.95). Facial deformities or disharmonies

were due to congenital deformities, trauma, tumor resection, or aging (Table 1).

The surgical technique consisted of intraoral or external incisions, including subciliary and endonasal assessments, or incision through preexisting scars. This was followed by dissection in planes, incision, and careful detachment of the periosteum. This step requires special attention, to avoid overexposure of the surgical bed where the biomaterial will be implanted, particularly when granules are used. Limited detachment of the periosteum and exposure of the underlying bone will help the maintenance of the granules in place, in the immediate postoperative period. Bioceramics are applied directly into the defect or are mixed with the patient's own blood, immediately before implantation. Care must be taken during application of the bioceramics, as the granules may fall off the curette or the instrument being used and may adhere to surrounding soft tissues. Their removal can take time and sometimes it is only achieved through the use of tweezers, with the removal of the granules one-by-one. No extra volume of bioceramics should be applied. In the case of customized parts, small adjustments can be made using drills, under constant irrigation, if necessary. Once the bioceramics were implanted, periosteum and soft tissue were gently repositioned and sutured.

Facial and radiographic analyses, as well as reports regarding pain, inflammation, infection, and other clinical interurrences were retrieved from medical records. Patients were followed from 3 to 16 years after surgery.

RESULTS

Twenty patients were selected from a larger cohort. Those who had received BCP bioceramics as onlay implants, who had been followed up for more than 3 years and who could be contacted and agreed to sign the informed consent, were included in this study. Nineteen patients received bioceramics as granules, through either external or intraoral incisions. In one patient (16), a custom-made prosthesis, for chin augmentation, was applied. Biomaterial was implanted on the frontal bone, nose, mid-face, or chin in 2 (10%), 2 (10%), 5 (25%), and 11 (55%) patients, respectively.

Most of the patients subjected to facial recontour and harmonization due to signs of aging (13, 16–20)

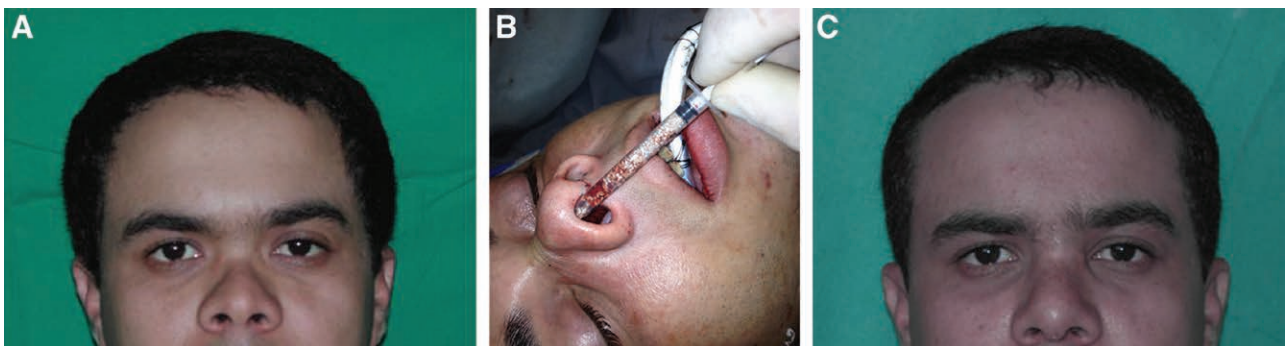


Fig. 1. Recontour of the nasal bridge due to sequelae of facial trauma with granules of BCP bioceramics. A, Preoperative. B, Application of bioceramics. C, 4 months postoperative.

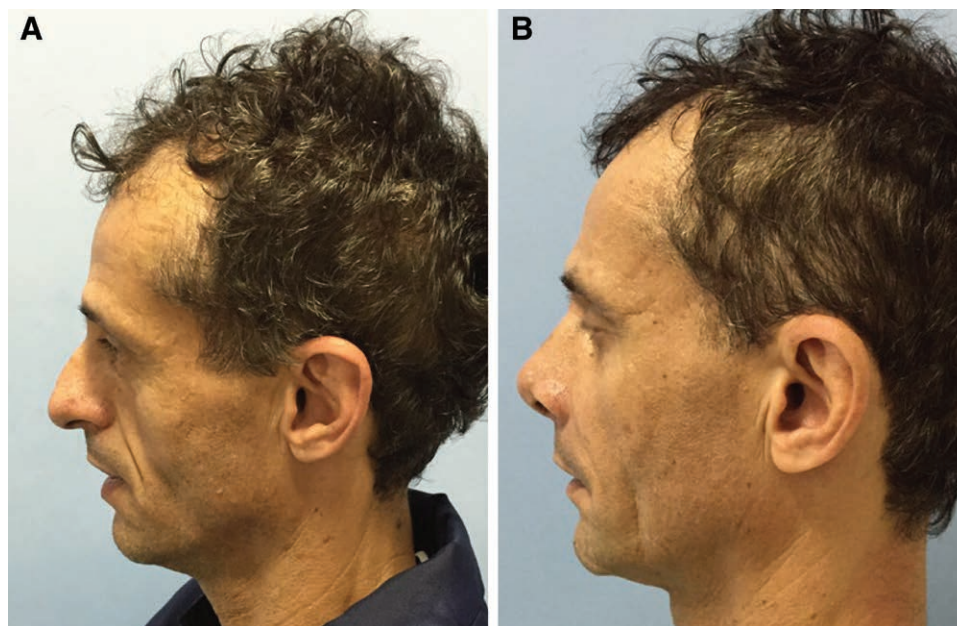


Fig. 2. Augmentation of the midface associated with rhinoplasty. A, Preoperative. B, 4 months postoperative.

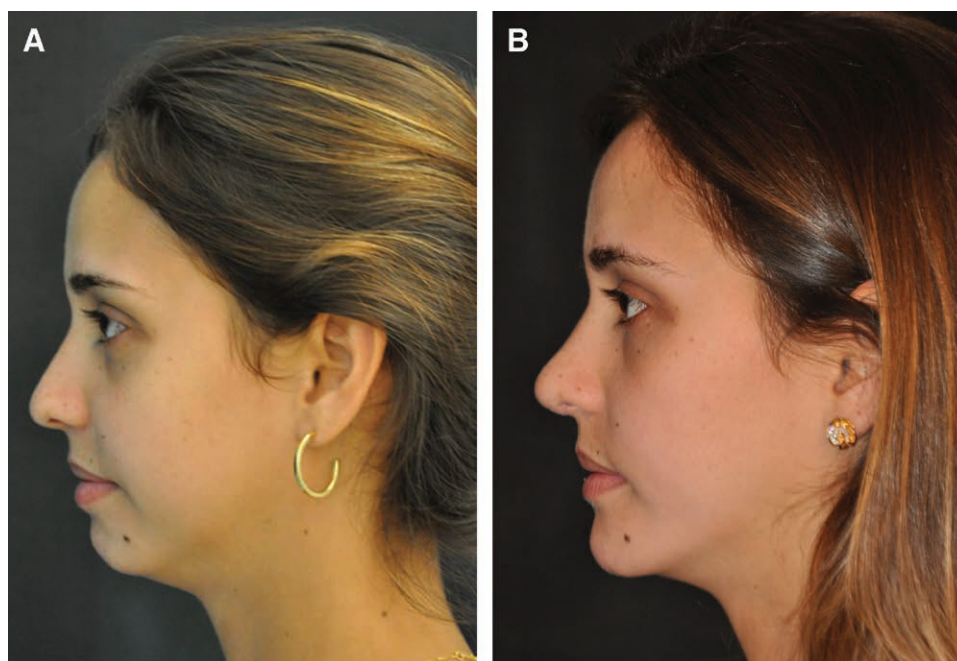

Fig. 3. Pre and postoperative aspects after chin augmentation with bioceramics and rhinoplasty. A, Preoperative. B, 1 year postoperative.

complained of facial flaccidity (5 of 6 patients) and were older than 42 years. All of them received implants on the chin (mentoplasty), combined with facial lifting or liposuction. Five patients were subjected to surgery due to trauma (25%); 1 due to tumor (5%) and 9 due to congenital/developmental facial disharmonies (45%). Most patients with trauma were men (4 of 5 patients) and presented bone defects on the upper and middle portions of the face.

The oldest patient in this study (64 years) presented a sequelae of large tumor resection and was the only patient subjected to 2 surgical procedures, 4 months apart. In both surgeries, bioceramics were implanted: the first was for reconstruction of the zygomatic arch and maxilla, and the second for augmentation of the zygomatic area.

In all cases, bioceramics were implanted under the periosteum, through incisions made in preexisting scars (common in patients with facial trauma) or via intraoral,

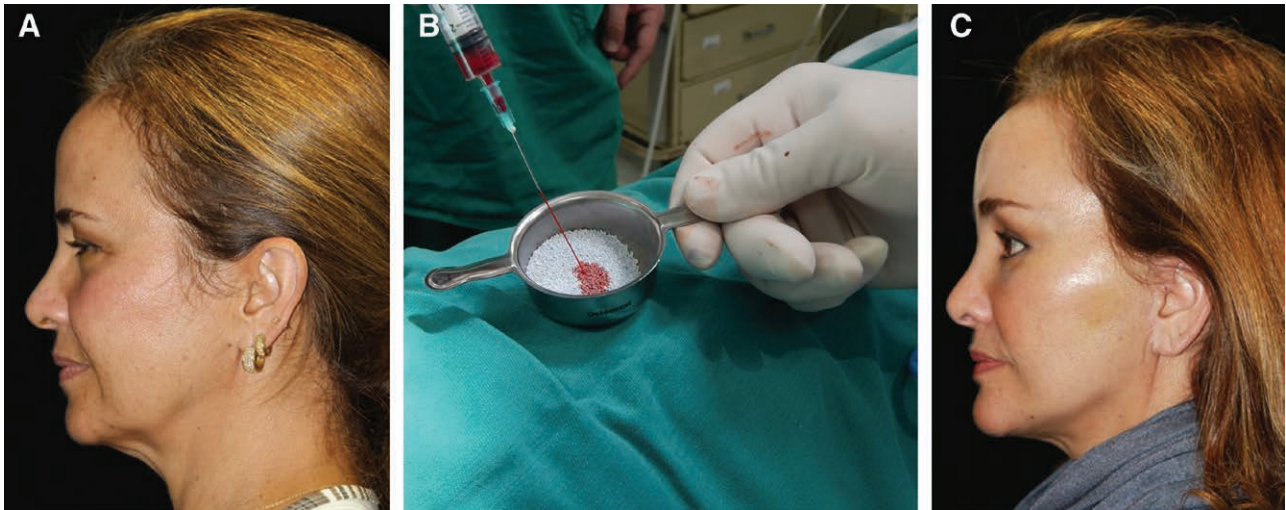

Fig. 4. Pre and postoperative aspects after mentoplasty with bioceramics and facial lifting. A, Preoperative. B, Mixing the bioceramics with patient’s blood, immediately before implantation. C, 7 months postoperative.

endonasal or subciliary approaches. This, in fact, was applied in 3 patients with congenital deformities that required augmentation of the midfacial bones, at the zygomatic-maxillary area.

None of the patients reported exacerbated pain or had signs of unusual inflammation after receiving the biomaterial, except for 1 (patient 15). This patient had an orthodontic apparatus when surgery was performed and developed an infection at the intraoral incision, which resolved following 7 days of antibiotic therapy. No further intervention was required. No other complications were reported in the postoperative period. Patients recovered well, did not require another surgical intervention, and presented stable and satisfactory aesthetic results over time.

Some patients reported slight movements of granules, soon after surgery and for up to 6 days postoperatively if the implanted area was intentionally pressed. However, no patient presented migration of the granules to the surrounding areas, nor had any compromise in the aesthetic result.

DISCUSSION

Soft tissue loss, depressed scars, muscle-mediated skin creases, and right-left functional asymmetries are commonly corrected with injections of fillers and/or neuromodulators and often require re-injections.⁹ Augmentation of depressed portions of the craniofacial skeleton, particularly of the cranial, frontal, nasal, zygomatic, and/or orbital bones, are often treated either with autografts, allografts, xenografts, or alloplastic (synthetic) biomaterials, to restore function and/or to improve aesthetics.^{13,14}

Although autografts (bone, costal, or conchal cartilages) have been historically regarded as the gold standard (whereas BCP bioceramics are the gold standard among alloplastic biomaterials), their shortcomings are well known and include: unpredictable resorption rates; limited availability; additional pain, risks and sequelae, such as scars at the harvesting site and pneumothorax; and difficulty to be tailored into an appropriate shape.^{1-3,10,13,15,21,23} These shortcomings, combined with numerous developments in biomaterials science, have led to several

Table 1. Description of Patients, Implantation Site, and Combined Surgical Procedures

ID	Age	Gender	Etiology/Complaint	Implantation Site	Associated Procedures
1	43	Woman	Trauma	Frontal bone	
2	42	Man	Trauma	Frontal bone	
3	19	Man	Trauma	Nose	
4	23	Man	Trauma	Nose	
5	43	Man	Trauma	Midfacial augmentation	
6	64	Woman	Tumor	Midfacial augmentation	Two surgeries
7	36	Woman	Midface hypoplasia	Midfacial augmentation	
8	26	Woman	Midface hypoplasia	Midfacial augmentation	
9	38	Man	Midface hypoplasia	Midfacial augmentation	
10	28	Woman	Hypoplasia of the chin	Chin	Rhinoplasty
11	21	Woman	Hypoplasia of the chin	Chin	Rhinoplasty
12	23	Man	Hypoplasia of the chin	Chin	
13	45	Woman	Hypoplasia of the chin	Chin	Facial lifting
14	23	Woman	Hypoplasia of the chin	Chin	Rhinoplasty
15	27	Woman	Hypoplasia of the chin	Chin	Rhinoplasty
16	42	Woman	Facial flaccidity	Chin	Facial lifting
17	48	Woman	Facial flaccidity	Chin	Facial lifting
18	58	Woman	Facial flaccidity	Chin	Facial lifting, liposuction
19	52	Woman	Facial flaccidity	Chin	Facial lifting
20	58	Woman	Facial flaccidity	Chin	Facial lifting, liposculpture

Table 2. Comparison of Pros and Cons of Autographs and BCP Bioceramics

Graph x Implant	Pros	Cons
Autographs	<ul style="list-style-type: none"> – Osteogenic capacity – Biocompatible – Osteoconductor – Osteoinductor 	<ul style="list-style-type: none"> – Require a second surgery to be harvested – Increased surgical time – Additional pain, risks, and sequelae – More blood loss – Unpredictable resorption rate
Biphasic calcium phosphate bioceramics, with interconnected pores	<ul style="list-style-type: none"> – Biomimetic – Biocompatible – Osteoconductor – Intrinsic osteoinduction capacity – Bioactive – It does not require a second surgery to be harvested – Decreased surgical time – Less pain, risks, and sequelae – Less blood loss – It will not be fully resorbed until a new bone is formed – It can be used as a carrier for drugs and other bioactive molecules 	<ul style="list-style-type: none"> – May take longer to regenerate – Cost

paradigm shifts (Table 2). Physicochemical features of synthetic biomaterials can be tailored, to improve and to modulate their interactions with host cells, including those involved in the immune response. For instance, some biomaterials can induce bone formation, without the addition of exogenous bioactive molecules (eg, BMP), a property called intrinsic osteoinduction capacity, which promotes tissue regeneration and not only tissue substitution. Moreover, several concepts, including biocompatibility and the definition of gold-standard material for bone reconstructions, have been substantially revised.^{12,23}

It is well established that micro- and macroporous BCP bioceramics are biocompatible, biomimetic, and capable of osteoconduction and intrinsic osteoinduction.^{22,23,26} They belong to the family of calcium phosphate-based biomaterials, which includes HAs, β -TCPs, and α -TCPs. Biphasic calcium phosphate (BCP) bioceramics are composed of an intimate mixture of HA and β -TCP.^{18,26} An important advantage of BCP is their controlled dissolution and/or resorption rate, which can be achieved by modulating the concentration of HA (corresponding to the crystalline phase, presenting slower resorption) and β -TCP (the amorphous phase, that has faster dissolution).^{22,23,27} Furthermore, depending upon the fabrication process, these bioceramics can be produced with various porosities and surface topographies and in distinct presentation forms, such as granules of various sizes, blocks, custom-made pieces, wedges, and cages.

BCP bioceramics have been widely and successfully applied in orthopaedics and craniofacial reconstructions and as scaffolds for stem cells in bone tissue engineering strategies.^{21–24,28} HAs have also been successfully applied as dermal filler to treat conditions related to aging.⁸ An important difference between bioceramics used as dermal fillers and the ones applied for bone reconstructions in granules, including those indicated as onlay implants, correspond to the size of the particles. The size of the granules used in this study ranged from 250 and 450 μm , with micropores varying from 10 to 100 μm and macropores, from 100 to 150 μm . Conversely, dermal fillers usually present particles ranging from 25 to 45 μm . Particle size is an important parameter to be considered as, for instance,

small particles rarely present pores, may induce fibrosis or be subject to phagocytosis, a process that should not be misled with resorption. Granules used for bone reconstruction should favor and induce bone formation, be resorbed only as a new bone is formed, or remain in place without being phagocytosed, for stable long-term clinical results.¹¹

The selection of the type of biomaterial must be guided by the knowledge of its biological response and mechanical properties. Biomaterials that suffer deflections or fractures even under minimal pressure or that are resorbed, resulting in secondary defects, are not good treatment options. Likewise, biomaterials that elicit foreign body reactions, with phagocytic attack and encapsulation by fibrous tissue, are the main cause of failure of several medical devices.¹⁷ Although biomaterials with such response may remain at the surgical site as they become entrapped by fibrosis, they should be considered biotolerant rather than biocompatible.^{12,23}

For instance, several polymeric biomaterials display exothermic reactions during curing and may release cytotoxic residual monomers; furthermore, they can also stimulate a substantial inflammatory response and cause edema, erythema, and other side effects.^{14,29} These negative outcomes are more likely to occur when polymers are prepared immediately before implantation (hand-formed).³⁰ Although improvement of facial recontour has been reported with these biomaterials, they usually lead to the formation of fibrous capsules, and rely on plates and/or screws to be stabilized.^{4,12,14,17} Therefore, choosing an implant that triggers a more appropriate tissue response is crucial.¹⁷

Whereas chemical composition has a substantial influence on whether a biomaterial is biocompatible or bioinert, its physical structure affects aspects such as mechanical resistance, cell adhesion, proliferation, differentiation, and adsorption of body fluids and bioactive molecules. These features and properties must be understood and, in conjunction with adequate presentation form, also influence the choice of the best biomaterial for a given application.^{22,24}

The interconnected macro- and microporosity of bioceramics favor the adsorption of patients' own proteins and bioactive molecules as well as the formation of a

fibrin network around and inside it.^{11,19,20,22–24,26} Thus, mixing bioceramic in granules with patients' blood, immediately before implantation, promotes its agglutination, facilitating the handling and application. However, this procedure should not alter the aspect of the biomaterial; ie, granules should not dissolve or become a paste before implantation.

This procedure also promotes stabilization of the granules, avoids adhesion of the particles to the surrounding soft tissues, and limits their micromovements at the surgical site, during the immediate and early postoperative periods. Although discrete movements of granules allow minor adjustments of the implant within the first 4–6 days after surgery, the patient must be advised that it may also cause an unpleasant sensation. Although granule movement could lead to aesthetic compromise if intense pressure was applied, this was not observed in this study.

To avoid such complications, a controlled and limited detachment of the periosteum and application of the granules under it ensure stabilization of the biomaterial at the surgical site. Furthermore, overcorrection of the area, commonly performed with autografts, is not indicated when these bioceramics are used because they are stable over time and will not resorb until a new bone is formed. The time required for a new bone formation to occur depends on several factors, such as age of the patient, quality of the adjacent bone, type of defect, and volume to be reconstructed.^{11,24} For instance, in the reconstructions of segmental bone defects of more than 3 cm in length, it may be necessary to mix the bioceramics with autologous bone grafts, cells or other bioactive molecules, or even to perform more than one surgical procedure, to favor and to allow bone formation.²⁴ But in all cases, having a biomaterial that is biocompatible and stable (ie, controlled resorption rate) is critical for successful clinical outcomes, particularly when they are used as onlay grafts.

Although septic complications have been reported with the use of porous HA prosthesis in cranioplasties,³¹ they are regarded as the biomaterial with lower risks of complications.³⁰ In this study, one patient that was under orthodontic treatment presented infection at the site of the intraoral incision. Orthodontic appliances easily retain food waste and require special oral hygiene care. Asepsis in these patients should be performed with extra attention, particularly if intraoral surgical access will be performed.

In this study, all cases were handled by the same surgeon, who has extensive experience in the field. Although the handling of the bioceramics is simple, the attention to the details previously described and the use of the appropriate surgical technique can guarantee the success or failure of the cases. The absolute standardization of the size and location of the bone defects to be reconstructed is extremely difficult, if not impossible, in clinical studies. Despite this, even with the clinical variations inherent to each patient, the biomaterial and technique presented here proved to be effective, allowing predictable and stable results in the long term. However, these results cannot be extrapolated to bioceramics with other chemical compositions and with different physical features.

It is important to emphasize that, in addition to the appropriate preparation of the surgical site, the quality of the soft tissue and/or the skin flap that will cover the bioceramics is also crucial. The same principles routinely used for bone grafts must be applied to biomaterials. Adequate coverage of the BCP with soft tissues, without tension and proper blood supply, has a direct impact on clinical results.

The lack of histological analysis of samples obtained from the patients reported in this study, and the lack of clinical results from patients operated on by other professionals and of cases performed with other biomaterials, whose results could be compared, represent limitations of this work. However, these may be future steps to be planned based on proof of the effectiveness of the technique presented here.

CONCLUSIONS

Although numerous surgical procedures and injections of biomaterials have been widely performed in soft tissues to improve facial aesthetics, correction of bone volume and position (commonly affected in aging and diseases) is essential. BCP bioceramics are safe, biomimetic, biocompatible, easy to handle, stable over time, and do not require overcorrection (ie, there is no need to use extra volume). BCP bioceramics, in the form of granules applied under the periosteum as onlay grafts, have predictable results and are a safe alternative to restore the facial contour and harmony of patients affected by congenital deformities, trauma, tumors, or aging.

Sonja Ellen Lobo, DDS, MSc, PhD
Avenida André Cavalcanti
63, Bairro Gutierrez
CEP 31441-025, Belo Horizonte
Minas Gerais, Brazil
E-mail: sonja.e.lobo@gmail.com

PATIENT CONSENT

Patients provided written consent for the use of their images.

REFERENCES

- Guerrerosantos J. Recontouring of the middle third of the face with onlay cartilage plus free fascia graft. *Ann Plast Surg.* 1987;18:409–420.
- Romano JJ, Iliff NT, Manson PN. Use of Medpor porous polyethylene implants in 140 patients with facial fractures. *J Craniofac Surg.* 1993;4:142–147.
- Collawn SS, Fix RJ, Moore JR, et al. Nasal cartilage grafts: More than a decade of experience. *Plast Reconstr Surg.* 1997;100:1547–1552.
- Deshpande S, Munoli A. Long-term results of high-density porous polyethylene implants in facial skeletal augmentation: An Indian perspective. *Indian J Plast Surg.* 2010;43:34–39.
- Yuan J, Cao Y, Liu W. Biomimetic scaffolds: Implications for craniofacial regeneration. *J Craniofac Surg.* 2012;23:294–297.
- Bernardini FP, Gennai A, Izzo L, et al. Superficial enhanced fluid fat injection (SEFFI) to correct volume defects and skin aging of the face and periocular region. *Aesthet Surg J.* 2015;35:504–515.
- Chou CK, Lee SS, Lin TY, et al. Micro-autologous fat transplantation (MAFT) for forehead volumizing and contouring. *Aesthetic Plast Surg.* 2017;41:845–855.

8. Pavicic T, Few JW, Huber-Vorländer J. A novel, multistep, combination facial rejuvenation procedure for treatment of the whole face with incobotulinumtoxinA, and two dermal fillers—calcium hydroxylapatite and a monophasic, polydensified hyaluronic acid filler. *J Drugs Dermatol*. 2013;12:978–984.
9. Alam M, Tung R. Injection technique in neurotoxins and fillers: Indications, products, and outcomes. *J Am Acad Dermatol*. 2018;79:423–435.
10. Atagi T, Young V. Alloplastic Materials. In: Mathes SJ, ed. *Plastic Surgery*. Philadelphia, PA: Saunders; 2006:745–766.
11. Lobo SE, Arinzeh TL. Biphasic calcium phosphate ceramics for bone regeneration and tissue engineering applications. *Materials (Basel)*. 2010;3:815–26.
12. Ratner, BD. Healing with medical implants: The body battles back. *Sci Transl Med*. 2015;7:272fs4.
13. Abdo Filho RC, Oliveira TM, Lourenço Neto N, et al. Reconstruction of bony facial contour deficiencies with polymethylmethacrylate implants: Case report. *J Appl Oral Sci*. 2011;19:426–430.
14. Limongi RM, Tao J, Borba A, et al. Complications and Management of Polymethylmethacrylate (PMMA) Injections to the Midface. *Aesthet Surg J*. 2016;36:132–135.
15. Chim H, Gosain AK. Biomaterials in craniofacial surgery: Experimental studies and clinical application. *J Craniofac Surg*. 2009;20:29–33.
16. Ratner BD. The biocompatibility manifesto: Biocompatibility for the twenty-first century. *J Cardiovasc Transl Res*. 2011;4:523–527.
17. Bryers JD, Giachelli CM, Ratner BD. Engineering biomaterials to integrate and heal: The biocompatibility paradigm shifts. *Biotechnol Bioeng*. 2012;109:1898–1911.
18. LeGeros RZ, Lin S, Rohanizadeh R, et al. Biphasic calcium phosphate bioceramics: Preparation, properties and applications. *J Mater Sci Mater Med*. 2003;14:201–209.
19. Nihouannen D Le, Saffarzadeh A, Aguado E, et al. Osteogenic properties of calcium phosphate ceramics and fibrin glue based composites. *J Mater Sci Mater Med*. 2007;18:225–35.
20. Lobo SE, Wykrota FH, Oliveira AC, et al. Quantification of bone mass gain in response to the application of biphasic bioceramics and platelet concentrate in critical-size bone defects. *J Mater Sci Mater Med*. 2009;20:1137–1147.
21. Stefani R, Esposito G, Zanotti B, et al. Use of “custom made” porous hydroxyapatite implants for cranioplasty: Postoperative analysis of complications in 1549 patients. *Surg Neurol Int*. 2013;4:12.
22. Lobo SE, Glickman R, da Silva WN, et al. Response of stem cells from different origins to biphasic calcium phosphate bioceramics. *Cell Tissue Res*. 2015;361:477–495.
23. Boulter JM, Pilet P, Gauthier O, et al. Biphasic calcium phosphate ceramics for bone reconstruction: A review of biological response. *Acta Biomater*. 2017;53:1–12.
24. Garrido CA, Lobo SE, Turíbio FM, et al. Biphasic calcium phosphate bioceramics for orthopaedic reconstructions: Clinical outcomes. *Int J Biomater*. 2011;2011:129727.
25. de Oliveira RS, Brigato R, Madureira JF, et al. Reconstruction of a large complex skull defect in a child: A case report and literature review. *Childs Nerv Syst*. 2007;23:1097–1102.
26. Daculsi G, Laboux O, Malard O, et al. Current state of the art of biphasic calcium phosphate bioceramics. *J Mater Sci Mater Med*. 2003;14:195–200.
27. Eliaz N, Metoki N. Calcium phosphate bioceramics: A review of their history, structure, properties, coating technologies and biomedical applications. *Materials (Basel)*. 2017;10:E334.
28. Gjerde C, Mustafa K, Hellem S, et al. Cell therapy induced regeneration of severely atrophied mandibular bone in a clinical trial. *Stem Cell Res Ther*. 2018;9:213.
29. Walt MJ, Atwood N, Bernatchez SF, et al. Skin protectants made of curable polymers: Effect of application on local skin temperature. *Adv Wound Care (New Rochelle)*. 2017;6:109–114.
30. Kwarcinski J, Boughton P, Ruys A, et al. Cranioplasty and craniofacial reconstruction: A review of implant material, manufacturing method and infection risk. *Appl Sci*. 2017;7:276.
31. Iaccarino C, Mattogno PP, Zanotti B, et al. Septic complication following porous hydroxyapatite cranioplasty: Prosthesis retention management. *J Neurosurg Sci*. 2018;62:765–772.